

# Investigation of the Effect of Organic Acid Addition to White Layer Akbay Line Chickens' Water on Villi and Some Egg Quality Parameters

Ayten AŞKIN KILINÇ<sup>1</sup>  Murat DOĞU<sup>2</sup>  Funda TERZİ<sup>3</sup>  Bahadır KILINÇ<sup>4\*</sup> 

<sup>1</sup> Poultry Research Institute, Ankara, Türkiye

<sup>2</sup> Poultry Research Institute, Ankara, Türkiye

<sup>3</sup> Kastamonu University, Faculty of Veterinary Medicine, Department of Pathology, Kastamonu, Türkiye

<sup>4\*</sup> Veterinary Control Central Research Institute Ankara, Türkiye

## Article Info

## ABSTRACT

### Article History

**Received:** 02.05.2024

**Accepted:** 14.06.2024

**Published:** 31.07.2024

### Keywords:

Akbay Line,  
Organic acid,  
White Layer,  
Intestinal Villi,  
Egg Quality.

Organic acids are carboxylic acids with the R-COOH structure and are released naturally through metabolic events. Organic acids are widely used as preservatives in poultry feed, especially to keep mold and other microorganisms under control. Organic acids are grouped according to the number of carbon atoms and carboxyl groups in their structures. Purpose of this study was to investigate the effects of increasing amounts of organic acid addition (Lactic acid, Formic acid, Propionic acid and Acetic acid) to laying hen rations on some parameters of egg quality, productivity and intestinal villi. In the study, 180 Akbay white laying hens at the age of 40 weeks were distributed to 3 groups and 6 replicates. Ad libitum drinking water was added to CN group chickens, 1 L/1000 L and 2 L/1000 L organic acid (85% Formic acid, Propionic acid, 80% Lactic Acid, 80% Acetic Acid) was added to the water of OAM-1 and OAM-2 group chickens and it was given 30 days. There was no statistically significant difference in the length measurement of intestinal duodenum, jejunum and ileum villi between the control and the groups to which organic acid was added ( $P>0.05$ ). There was no lesion in the histopathological examination of the intestines. Egg productivity parameters such as egg weight, yolk color index, albumen height, Haugh unit and strength were found to be statistically significant between the groups ( $P<0.05$ ). As a result, it is thought that it would be appropriate to add organic acid to the drinking water of laying hens for shell quality and quality egg production.

### To cite this article:

Aşkın Kılınç, A., Doğu, M., Terzi F. & Kılınç B. (2024). Investigation of the effect of organic acid addition to white layer akbay line chickens' water on villi and some egg quality parameters. *Research and Practice in Veterinary and Animal Science (REPVAS)*, 1(2), 86- 94. <https://doi.org/10.69990/repvas.2024.1.2.4>

\*Corresponding Author: Bahadır Kılınç, [patbhdr@gmail.com](mailto:patbhdr@gmail.com)



## **INTRODUCTION**

In poultry and wild birds, it is important to reveal histopathological changes and closely examine the intestines for the continuity of a balanced ecosystem (Kanat, 2024). Chronic or acute inflammations occurring in the small intestine mucosa can cause destruction of the villi (Yıldırım E., 2020). Increasing intestinal villi and improving egg quality are of great importance for commercial enterprises. Apart from organic acid compounds, there are also studies on yeast additions to diets (Gül et al., 2013). In commercial poultry farms, different feed additives have been used to prevent the colonization of intestinal pathogenic microorganisms, support the immune system and increase their performance (Islam et al., 2008). One of the feed additives used is organic acids.

The chemical structures of compounds called organic acids and carboxylic acids depend on the carbon skeleton (Kum and Güçlü 2006). It has been reported that there are nearly sixty classes of organic acids naturally obtained from animals, plants and microorganisms. Some of these are lactic acid, formic acid, citric acid, fumaric acid (Park et al., 2009). Organic acids (OAs), a suitable alternative to antibiotics, have positive effects on intestinal health and bird performance (Adams, 1999; Rathnayake et al. 2021; Sak and Soykut, 2021). In addition, organic acids prevent the formation of mold and mycotoxins (Nir and Şenköylü, 2000).

Organic acids, which are added to feed or drinking water, have an antibacterial effect with their insoluble parts (İpçak et al., 2017). Organic acids lower gastric pH, rapidly convert pepsinogen into pepsin, stimulating the absorption of amino acids, proteins and minerals. (Park et al. 2009; Yeşilbağ et al. 2007). Studies have shown that the addition of organic acids to diets causes significant changes in the small intestinal microflora (Bozkurt and Sandıkçı, 2009; Gül, 2017; Yeşilbağ et al. 2007). They do not leave residue in the body after being metabolized in the organism.

Due to the expansion of the small intestine villus surface, there is an increase in absorption and utilization of nutrients. (Kara et al., 2013). Egg quality is important not only for consumer preferences but also for producers as economic gain (Akkuş and Yıldırım, 2018). In-house management is among the factors that determine quality. Egg shell quality and durability are also important in terms of hatching use, marketing, and nutritional values. (Akkuş and Yıldırım, 2018).

The purpose of this study is to investigate the effect of organic acid addition to the drinking water of white laying hen Akbay line on intestinal villus length and egg quality.

## **MATERIAL AND METHOD**

### **Animal**

Ethical permission was obtained from the Local Ethics Committee of Poultry Research Institute Directorate (TAE-HADYEK) (approval no: 2023/02). The animal material of the study consisted of 180 40-week-old white layer Akbay chickens. The composition of the commercial organic acid (MOLDCID LIQUID, VİMAR®, Türkiye) used in the experiment is Formic acid (85%), Propionic acid, Lactic Acid (80%) and Acetic Acid (80%). Feed was given to the chickens as ad libitum. Chickens were randomly placed into 3 groups and 6 replicates in a 3-layer battery type cage system.

### **Experimental Study**

**Control group (CN):** Drinking water without organic acids was given ad libitum.

**Organic Acid-1 group (OAM-1):** 1 L/1000 L organic acid was added to drinking water and given ad libitum.

**Organic Acid-2 group (OAM-2):** 2 L/1000 L organic acid was added to drinking water and administered ad libitum.

The study was completed on the 30th day. The jugular vein of 6 of 60 chickens in each group (1 from each replicate) was cut and necropsy was performed. Intestinal sections (duodenum, jejunum, ileum) were taken into 10% buffered formalin for histopathological examination.

### **Histopathological Examination**

Necropsies were performed on the chickens, and the tissues were kept in buffered 10% formalin for 48 hours. The tissues were kept under running tap water for 8 hours to remove formalin residues. The tissues were trimmed and transferred to tissue tracking cassettes. The tissue tracing process was passed through ascending alcohol series, xylene series and paraffin series and blocked with paraffin. 5 µm thick sections were taken from the obtained blocks. Sections were stained with the Hematoxylin-Eosin staining method (Luna, 1968). Sections were examined under a light microscope (Leica DM2500). Length measurements of the villi were made with the Leica Application Suite V4.12.0 program.

### **Determination of Egg Quality Parameters**

At the beginning and end of the experiment, internal and external quality characteristics (egg weight, breaking strength and shell thickness, albumin height, yolk color index and haugh unit) of 20 eggs randomly selected from each group were determined using the DET-6000-Digital Egg Tester measuring device (Nabel).

### **Statistical Analysis**

Data were analyzed using software package Minitab version 19. All values are presented as Mean ± Standard Error (SE). To test the significance of the difference in group comparisons, analysis of variance was performed in repeated measurements in independent groups at the 5% significance level. The assumption of homogeneity of variances was examined with the sphericity test. Intestinal villus length and egg quality parameters were statistically analyzed by one-way analysis of variance (ANOVA) between study groups. Significant differences were determined after the data were analyzed by Tukey's multiple range test.  $P < 0.05$  was considered to be statistically significant.

## **RESULTS**

### **Histopathological Results**

The villus lengths of the intestinal sections from the chickens of the control and treatment groups are given in Table 1. No statistically significant difference was found between the intestinal duodenum, jejunum and ileum villus lengths of the study group chickens to which organic acid was added to their water ( $P > 0.05$ , Fig 1 A-B-C). No pathological findings were found in the histopathological examinations performed on the intestinal sections.

**Table 1**

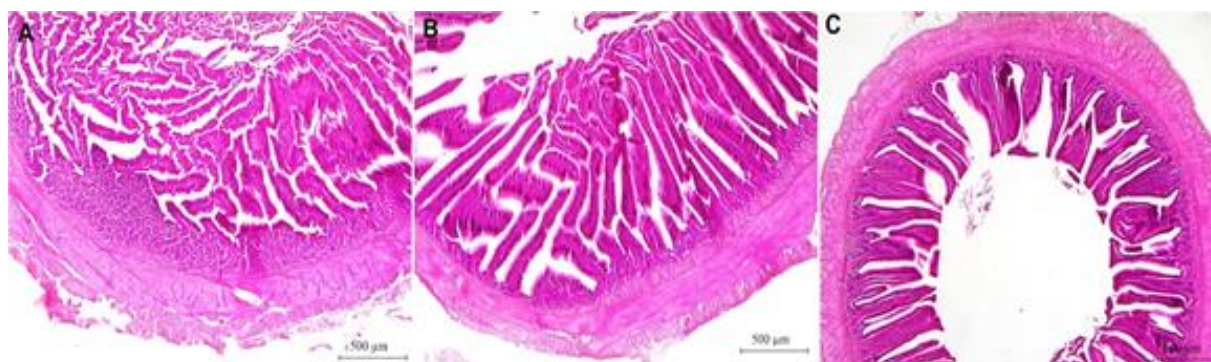
*Statistically Significant Differences in the Effect of Organic Acid Added to Drinking Water of White Layer Akbay Line Chickens on the Length of the Intestinal Duodenum, Jejunum and Ileum Villus*

Variable	Group	N	N*	Mean± SE	Minimum	Maximum	P value
Duodenum	CN	6	0	1436.0±57.6	1245.0	1595.0	0.171
	OAM-1	6	0	1352.5±27.4	1262.0	1431.0	
	OAM-2	6	0	1479.3±46.8	1374.0	1685.0	
Jejunum	CN	6	0	1040.8±64.4	879.0	1306.0	0.917
	OAM-1	6	0	1058.3±62.1	891.0	1254.0	
	OAM-2	6	0	1081.7±80.2	770.0	1323.0	
Ileum	CN	6	0	852.7±59.5	651.0	1028.0	0.769
	OAM-1	6	0	906.3±92.0	644.0	1178.0	
	OAM-2	6	0	918.5±42.4	790.0	1068.0	

**Figure 1**

*Normal Histological Appearance of the Intestine. White Layer Akbay Line Chicken.*

*A. Duodenum. Oam-2 Group. H&E. Bar:500 µm. B. Jejunum. Oam-1group. H&E.Bar:500 µm. C. Ileum. Oam-2 Group. H&E.Bar:500 µm.*



### **Egg Quality Parameters**

Findings regarding egg quality characteristics are given in Table 2. At the beginning of the study, the yellow color index of eggs taken from chickens was lowest in the OAM-2 group and highest in the OAM-1 group ( $P<0.05$ ). Additionally, there was no statistically significant difference between the groups in egg weight, shell thickness and strength and also Haugh unit ( $P>0.05$ ).

At the end of the experiment, egg weight and strength, yolk color index, Haugh unit, albumen height parameters were found to be statistically significant between control and treatment groups ( $P<0.05$ ). Egg weight and yolk color index were higher in the OAM-1 group, albumen height and Haugh unit were higher in the control group, and strength value was higher in the OAM-1 and OAM-2 groups ( $P<0.05$ ). There was no statistically significant difference in eggshell thickness between the control and treatment groups ( $P>0.05$ ).

### **DISCUSSION**

Three important elements of the gastrointestinal tract are the immune system, intestinal microbiota and epithelial cells. The main part of the intestine where the absorption of nutrients takes place is the small intestinal villi. Prebiotics, such as organic acids and essential oils, improve the

integrity of intestinal epithelial cells, additionally enhancing the absorption of molecules and improving the growth performance of productivity animals (Adil et al. 2010; Kaya et al. 2015). Organic acids like fumaric, citric, propionic and formic acids increase gastric proteolysis, significantly affecting the digestibility of proteins and amino acids. (Samanta, 2010). In this study, the effect of organic acid added to the drinking water of white layer Akbay chickens on intestinal villus length and egg quality was investigated.

**Table 2**

*Statistically Significant Differences in the Effect of Organic Acid Added to the Drink Water of White Layer Akbay Line Chickens on the Egg Quality Characteristics.*

	Variables	Group	N	Mean±SE	P value
Beginning of study	Egg Weight	CN	20	59.54± 0.59	0.160
		OAM-1	20	61.13± 0.90	
		OAM-2	20	61.88± 1.05	
	Albumen Height	CN	20	7.535± 0.14	0.264
		OAM-1	20	7.745±0.19	
		OAM-2	20	7.260± 0.27	
	Yolk Color Index	CN	20	11.245± 0.15 <sup>ab</sup>	0.020*
		OAM-1	20	11.680± 0.16 <sup>a</sup>	
		OAM-2	20	11.115± 0.11 <sup>b</sup>	
	Haugh Unit	CN	20	86.925± 0.80	0.119
		OAM-1	20	87.63± 1.01	
		OAM-2	20	84.15± 1.71	
	Strength	CN	20	44.97± 1.72	0.255
		OAM-1	20	44.65± 1.23	
		OAM-2	20	41.85± 1.36	
	Eggshell Thickness	CN	20	0.345± 0.00	0.376
		OAM-1	20	2.52± 2.18	
		OAM-2	20	0.344± 0.00	
End of study	Egg Weight	CN	20	59.420± 0.59 <sup>b</sup>	0.050*
		OAM-1	20	61.895± 0.83 <sup>a</sup>	
		OAM-2	20	60.155± 0.70 <sup>ab</sup>	
	Albumen Height	CN	20	7.450± 0.20 <sup>a</sup>	0.000*
		OAM-1	20	7.115± 0.58 <sup>a</sup>	
		OAM-2	20	4.940± 0.14 <sup>b</sup>	
	Yolk Color Index	CN	20	11.370± 0.08 <sup>ab</sup>	0.005*
		OAM-1	20	11.720± 0.15 <sup>a</sup>	
		OAM-2	20	11.045± 0.17 <sup>b</sup>	
	Haugh Unit	CN	20	86.33± 1.12 <sup>a</sup>	0.000*
		OAM-1	20	82.17± 2.44 <sup>a</sup>	
		OAM-2	20	67.73± 1.34 <sup>b</sup>	
	Strength	CN	20	37.79± 2.27 <sup>b</sup>	0.012*
		OAM-1	20	41.44± 1.94 <sup>a</sup>	
		OAM-2	20	46.69± 1.91 <sup>a</sup>	
	Eggshell Thickness	CN	20	0.336± 0.00	0.198
		OAM-1	20	0.345± 0.00	
		OAM-2	20	0.347± 0.00	

\*:P<0,05



Organic acids control the proliferation of many pathogenic and non-pathogenic intestinal bacteria. It also increases the height of villi and the secretion, digestion and absorption of nutrients by the mucosa by reducing inflammatory reactions in the intestinal mucosa (Adil et al. 2010; Samanta et al. 2010). In studies investigating organic acid on intestinal villus length in chickens, Samanta et al. (2010) reported that the villus height in the duodenum increased linearly with the dose of organic acid mixture. Found that organic acid dietary supplementation in broiler chickens significantly increased duodenum and jejunum villus length ( $P < 0.05$ ) compared to the control group. In this study, no statistically significant difference was found between the intestinal duodenum, jejunum and ileum villus lengths of the study group chickens to which organic acid was added to their water ( $P > 0.05$ ).

Eggs are foods that contains a high amount of animal protein and is cheap and easy to produce. In recent years, with the increase in human population, the demand for egg production has also increased (Ürüşan and Bölükbaşı, 2020). In addition, eggs increase antioxidant activity and phenolic substance content in foods offered for human consumption (Kömürcü and Bilgiçli, 2024).

It is important for eggs, which are important as a source of protein for humans, to have a strong shell. In laying hen farms, 8-10% of eggs break due to shell problems and this causes economic losses (Tabib and Onbaşlar, 2019). Egg shell thickness and breaking resistance, egg Haugh unit, yolk color index and albumen height are affected by feed and feed additives added to rations and drinking water (Ürüşan and Bölükbaşı, 2020). Organic acids maintain electrolyte balance by enabling anions to form compounds with minerals such as Ca, Mg, Zn and P in chicken diets and intestines (Kaya et al., 2014). In this study, it was determined that in the groups where organic acid was added to the water of chickens, egg weight and yellow color index increased in the OAM-1 group, and the strength value increased in the OAM-1 and OAM-2 groups ( $P < 0.05$ ). Kaya et al. (2020) added 0, 1.5, 3 and 4.5 kg/ton of organic acid to chicken rations for 13 weeks. It was determined that the rate of damaged eggs decreased and egg weight increased in the groups to which organic acid was added. Dama and Kaya (2018) reported in their study that adding propionic acid at increasing levels (0.100, 200 and 300 ppm) to laying hen rations caused changes in egg quality parameters (shell thickness and breaking strength, egg yellow color index, Haugh unit and albumen height). In this study, it is thought that adding 1 L/1000 L organic acid supplement to the water of chickens is more effective on egg quality.

In the conclusion, in our study, it was determined that the addition of organic acid to the drinking water of laying hens was effective on egg weight, shell breaking resistance, shell thickness and yellow color index. We think that it would be appropriate to add organic acid to the drinking water of laying hens for shell quality and profitable egg production.

Three important elements of the gastrointestinal tract are the immune system, intestinal microbiota and epithelial cells. The main part of the intestine where the absorption of nutrients takes place is the small intestinal villi. Prebiotics, such as organic acids and essential oils, improve the integrity of intestinal epithelial cells, additionally enhancing the absorption of molecules and improving the growth performance of productivity animals (Adil et al., 2010; Kaya et al., 2015). Organic acids like fumaric, citric, propionic and formic acids increase gastric proteolysis, significantly affecting the digestibility of proteins and amino acids. (Samanta, 2010). In this study, the effect of organic acid added to the drinking water of white layer Akbay chickens on intestinal villus length and egg quality was investigated.

Organic acids control the proliferation of many pathogenic and non-pathogenic intestinal bacteria. It also increases the height of villi and the secretion, digestion and absorption of nutrients by the mucosa by reducing inflammatory reactions in the intestinal mucosa (Adil et al., 2010, Samanta et al. 2010). In studies investigating organic acid on intestinal villus length in chickens, Samanta et al. (2010) reported that the villus height in the duodenum increased linearly with the dose of organic acid

mixture. Found that organic acid dietary supplementation in broiler chickens significantly increased duodenum and jejunum villus length ( $P<0.05$ ) compared to the control group. In this study, no statistically significant difference was found between the intestinal duodenum, jejunum and ileum villus lengths of the study group chickens to which organic acid was added to their water ( $P>0.05$ ).

Eggs are foods that contains a high amount of animal protein and is cheap and easy to produce. In recent years, with the increase in human population, the demand for egg production has also increased (Ürüşan and Bölükbaşı, 2020). In addition, eggs increase antioxidant activity and phenolic substance content in foods offered for human consumption (Kömürcü and Bilgiçli, 2024).

It is important for eggs, which are important as a source of protein for humans, to have a strong shell. In laying hen farms, 8-10% of eggs break due to shell problems and this causes economic losses (Tabib and Onbaşlar, 2019). Egg shell thickness and breaking resistance, egg Haugh unit, yolk color index and albumen height are affected by feed and feed additives added to rations and drinking water (Ürüşan and Bölükbaşı, 2020). Organic acids maintain electrolyte balance by enabling anions to form compounds with minerals such as Ca, Mg, Zn and P in chicken diets and intestines (Kaya et al., 2014). In this study, it was determined that in the groups where organic acid was added to the water of chickens, egg weight and yellow color index increased in the OAM-1 group, and the strength value increased in the OAM-1 and OAM-2 groups ( $P<0.05$ ). Kaya et al. (2020) added 0, 1.5, 3 and 4.5 kg/ton of organic acid to chicken rations for 13 weeks. It was determined that the rate of damaged eggs decreased and egg weight increased in the groups to which organic acid was added. Dama and Kaya (2018) reported in their study that adding propionic acid at increasing levels (0.100, 200 and 300 ppm) to laying hen rations caused changes in egg quality parameters (shell thickness and breaking strength, egg yellow color index, Haugh unit and albumen height). In this study, it is thought that adding 1 L/1000 L organic acid supplement to the water of chickens is more effective on egg quality.

In the conclusion, in our study, it was determined that the addition of organic acid to the drinking water of laying hens was effective on egg weight, shell breaking resistance, shell thickness and yellow color index. We think that it would be appropriate to add organic acid to the drinking water of laying hens for shell quality and profitable egg production.

#### **Ethics Committee Approval**

13/04/2023 dated and numbered 2023/02 was given by Local Ethics Committee of Poultry Research Institute Directorate (TAE-HADYEK).

#### **Author Contributions**

Study planning AAK, MD; Performing the experiment AAK, MD; Making analyzes FT, BK; Evaluation AAK, MD, FT, BK; Writing the final report FT, BK; Article publishing efforts BK

#### **Funding**

There is no financial support.

#### **Conflict of Interest**

The authors declared no potential conflicts of interest with respect to the research, authorship, and/or publication of this article.

#### **Sustainable Development Goals (SDG): 3 Good Health and Well-Being**

## REFERENCES

- Adams, C. (1999). Poultry and dietary acids. *Feed Int.* 20, 14-19.
- Adil, S., Banday, T., Bhat, G. A., Mir, M. S. & Rehman, M. (2010). Effect of dietary supplementation of organic acids on performance, intestinal histomorphology, and serum biochemistry of broiler chicken. *Veterinary Medicine International*, 2010.
- Akkuş, B. & Yıldırım, İ. (2018). Beyaz ve kahverengi ticari yumurtacı tavuklarda, tavuk yaşı ve kafes katının yumurta dış kalite parametreleri üzerine etkileri. *Akademik Ziraat Dergisi*, 7(2), 211-218.
- Altun, H. Ü. & Bölükbaşı, C. (2020). Yumurta kalitesini iyileştirici güncel besleme çalışmaları. *Dicle Üniversitesi Fen Bilimleri Enstitüsü Dergisi*, 9(1), 65-78.
- Bozkurt, M. & Sandıkçı, M. (2009). Farklı yaşlardaki civcivlerin barsak villus boyu ve çapı ile kadeh hücresi ve mitotik hücre sayılarındaki değişimler. *Yüzyüncü Yıl Üniversitesi Veteriner Fakültesi Dergisi*, 20(1), 5-9.
- Cankurtaran Kömürcü, T. & Bilgiçli, N. (2024). Yumurtalı ve yumurtasız formüle edilen madımak (*Polygonum cognatum*) tozu ilaveli eriştelerin fonksiyonel içeriği ve duyuşal özellikleri. *Necmettin Erbakan Üniversitesi Fen ve Mühendislik Bilimleri Dergisi*, 6(1), 124-138.
- Dama, G., & Kaya, A. (2018). Yumurtacı Tavuk Rasyonlarına Propiyonik Asit İlavesinin Performans, Yumurta Kalitesi ve Bazı Kan Parametreleri Üzerine Etkileri. *Tekirdağ Ziraat Fakültesi Dergisi*. 15(01) 129-134
- Gül, M., Yörük, M. A., Sağlam, Y. S. & Aksu, T. (2013). Yumurta tavuğu rasyonlarına maya (*Saccharomyces cerevisiae*) ve *Enterococcus faecium* katkılarının performans, yumurta kalite kriterleri ve barsak mikroflorası üzerine etkileri. *Atatürk Üniversitesi Veteriner Bilimleri Dergisi*, 8(2), 137-144.
- Gül M, (2017). Organik asitler: organik asitler ve hayvan beslemede kullanım alanları. *Türkiye Klinikleri J Anim Nutr&Nutr Dis-Special Topics*, 3(1), 57-63.
- Islam, M.Z., Khandaker1, Z.H., Chowdhury, S.D. & Islam, K.M.S. 2008. Effect of citric acid and acetic acid on the performance of broilers. *J. Bangladesh Agril. Univ.* 6(2), 315–320.
- İpçak, H. H., Özüretmen, S., Özelçam, H. & Ünlü, H. B. (2017). Hayvan beslemede antibiyotiklere alternatif olarak organik asit, esansiyel yağ ve bakteriyosinlerin kullanımı. *Hayvansal Üretim*, 58(1), 57-65.
- Kanat, Ö. (2024). Histopathological investigation of gastrointestinal system parasites in storks: *Cathaemasia hians*. *Research and Practice in Veterinary and Animal Science (REPVAS)*, 1(1), 9-18
- Kara, A., Hira, F., Şimşek, N., Yörük, M. A. & Gümüş, R. (2013). İnorganik ve organik bakır, çinko ve mangan eklenen diyetlerle beslenen yumurta tavuklarının ince bağırsak morfolojisi üzerine histokimyasal ve histometrik bir çalışma. *Atatürk Üniversitesi Vet. Bil. Derg.* 2013, 8(1), 53-61.
- Kaya, A., Kaya, H., Gül, M. & Çelebi, Ş. (2014). Geç dönemde organik asit ilavesinin yumurtlama



- performansı, yumurta kalite özellikleri ve bağırsak pH'sı üzerine etkisi. *Atatürk Üniversitesi Ziraat Fakültesi Dergisi*, 45(1), 37-41.
- Kaya, A., Kaya, H., Gül, M., Yıldırım, A. & Timurkan, B. (2015). Effect of different levels of organic acids in the diets of hens on laying performance, egg quality criteria, blood parameters, and intestinal histomorphology. *Indian Journal of Animal Research*, 49(5) 645-651
- Kum E. & Kocaoğlu Güçlü B. (2006). Standart ve sıkışık kafes yoğunluğunda yetiştirilen Yumurta tavuğu karma yemlerine organik asit ilavesinin performansına etkisi. *Sağlık Bilimleri Dergisi (Journal of Health Sciences)*, 15(2), 99-106.
- Luna LG (1968) Manual of histologic staining methods of the armed forces institute of pathology, 3rd ed. McGrawHill, New York, NY.
- Nir, I. & Şenkoylu, N. (2000). Kanatlılar İçin Sindirimi Destekleyen Yem Katkı Maddeleri. ISBN 975-93691-0-9. Tekirdağ.
- Onbaşlar, E. E. & Tabib, İ. (2019). Tavuklarda yumurta kabuğunun yapısı ve kabuk kalitesini etkileyen faktörler. *Journal of Poultry Research*, 16(2), 48-54.
- Park KW, Rhee AR, Um SJ & Paik IK, (2009). Effect of dietary available phosphorus and organic acids on the performance and egg quality of laying hens. *J. Appl. Poult. Res.*, 18, 598-604.
- Rathnayake, D., Mun, H. S., Dilawar, M. A., Baek, K. S. & Yang, C. J. (2021). Time for a paradigm shift in animal nutrition metabolic pathway: Dietary inclusion of organic acids on the production parameters, nutrient digestibility, and meat quality traits of swine and broilers. *Life*, 11(6), 476.
- Sak, D. & Soykut, G. (2021). Biyotikler ailesinin yeni üyesi postbiyotikler. *Genel Sağlık Bilimleri Dergisi*, 3(3), 259-272.
- Samanta, S., Halder, S., & Ghosh, T. K. (2010). Comparative efficacy of an organic acid blend and bacitracin methylene disalicylate as growth promoters in broiler chickens: effects on performance, gut histology, and small intestinal milieu. *Veterinary medicine international*, 2010(1), 645150.
- Selvi, M. H. (2024). The use of statistics in veterinary sciences and the test methods used. *Research and Practice in Veterinary and Animal Science (REPVAS)*, 1(1), 43-50.
- Yeşilbağ, D., Çiftçi, A., & Akan, M. (2007). Yumurta Tavuğu Rasyonuna İlave Edilen Organik Asit Karmasının İnce Bağırsak pH'sı ve Mikroflorası Üzerine Etkileri. *Uludağ Üniversitesi Veteriner Fakültesi Dergisi*, 26(1-2), 21-26.
- Yıldırım, E. (2020). Çölyak hastalığı ve glutensiz besleme. *Genel Sağlık Bilimleri Dergisi*, 2(3), 175-187.