

## A Case of Proliferative and Necrotizing Otitis Externa in a Scottish Fold Shorthair Cat

Caner KAYIKCI<sup>1\*</sup> Ömer Faruk KELEŞ<sup>2</sup> Yağmur KUŞCU<sup>3</sup>  
Selime Nur EKİCİ<sup>4</sup> Hacı Ahmet ÇİÇEK<sup>5</sup>

<sup>1\*</sup> Van Yuzuncu Yil University, Faculty of Veterinary Medicine, Department of Surgery, Van, Türkiye

 <https://orcid.org/0000-0001-7343-1045>

<sup>2</sup> Van Yuzuncu Yil University, Faculty of Veterinary Medicine, Department of Pathology, Van, Türkiye

 <https://orcid.org/0000-0002-7869-5311>


<sup>3</sup> Van Yuzuncu Yil University, Faculty of Veterinary Medicine, Department of Surgery, Van, Türkiye

 <https://orcid.org/0000-0002-7802-5481>

<sup>4</sup> Van Yuzuncu Yil University, Faculty of Veterinary Medicine, Department of Surgery, Van, Türkiye, Türkiye

 <https://orcid.org/0009-0004-0158-5650>

<sup>5</sup> Van Yuzuncu Yil University, Faculty of Veterinary Medicine, Department of Pathology, Van, Türkiye

 <https://orcid.org/0009-0002-5154-7498>

### Article Info

### ABSTRACT

#### Article History

**Received:** 11.12.2023

**Accepted:** 15.01.2024

**Published:** 31.01.2024

#### Keywords:

PNOE,  
Cat,  
Ear,  
Histopathology.

#### \* Corresponding Author:

Caner KAYIKCI,  
[caner5246@hotmail.com](mailto:caner5246@hotmail.com)

In this case report, the aim was to contribute to understanding PNOE's clinical presentation, histopathological features, and successful treatment approaches, emphasizing the significance of accurate diagnosis and appropriate management in affected felines. Proliferative necrotic otitis externa (PNOE) is a very rare skin disease of unknown etiology affecting the vertical ear canal and the concave surface of the auricle, which may be accompanied by secondary yeast or bacterial infections. In this case 8-month-old Scottish fold shorthair cat has fragile, papillomatous growths and caseous purulent exudate in the ear canal was presented. The differential diagnosis of this condition includes otoacariasis, plasma cell pododermatitis, papillomavirus and chronic bacterial or yeast otitis externa. Despite antimicrobial and antiparasitic based previous treatments, the lesions persisted. Histopathological examination revealed acanthotic epidermis, necrotic keratinocytes, and inflammatory cell infiltrates. Treatment involved methylprednisolone injection, topical pomades, and systemic antibiotics. The cat showed improvement after initial treatment week, with regression of lesions and cessation of ear discharge. Follow-up visits demonstrated continued improvement, and after two months, minimal sequelae remained. In conclusion, despite the unknown etiology of PNOE, the disease is quite responsive to immunosuppressive therapy, which is beneficial for both diagnosis and treatment.

**Citation:** Kayıkcı, C., Keleş, Ö. F., Kuşcu, Y., Ekici, S. N., & Çiçek, H. A. (2024). A case of proliferative and necrotizing otitis externa in a Scottish fold shorthair cat. *Research and Practice in Veterinary and Animal Science (REPVAS)*, 1(1), 51-56.



"This article is licensed under a [Creative Commons Attribution-NonCommercial 4.0 International License](https://creativecommons.org/licenses/by-nc/4.0/) (CC BY-NC 4.0)"

## INTRODUCTION

Proliferative necrotic otitis externa (PNOE) is a very rare skin disease of unknown etiology affecting the vertical ear canal and the concave surface of the auricle, which may be accompanied by secondary yeast or bacterial infections (Mauldin *et al.*, 2007; Borio *et al.*, 2012; Momota *et al.*, 2016). Plaque like lesions appear between 2 and 6 months of age in affected animals (Mauldin *et al.*, 2007). Lesions may regress spontaneously within 12 to 24 months (Gross *et al.*, 2008). The presence of scattered apoptotic keratinocytes within the highly hyperplastic epidermis and superficial follicular epithelium is the most prominent feature on histopathological examination. Luminal folliculitis is also frequent manifestation. Superficial and luminal pustulation and eosinophilic micro-abscesses of the epidermis have rarely been documented. (Vidémont and Pin, 2010). Amorphous debris, inflammatory cells and cocci can be found in the smear prepared from the exudate (Momota *et al.*, 2016). The pathogenesis of the disease is still under investigation (Vidémont and Pin, 2010). Immunosuppressant drugs such as tacrolimus suppress inflammatory cells including T cells and inhibit keratinocyte hyperplasia by increasing cytokine production (Sanders *et al.*, 2002). Alternatives to tacrolimus include clobetasol propionate cream and local injection of methylprednisolone acetate into the lesion (Momota *et al.*, 2016). This disease, typically seen in kittens, should be considered among the differential diagnoses for bilateral otitis externa in young cats (Borio *et al.*, 2012).

In this case report, the clinical symptoms, pathological findings and treatment approach of PNOE are aimed to present.

## CASE HISTORY

Patient was presented to Van Yuzuncu Yil University, Animal hospital, Surgery department with the complaints of epiphora for 6 months and formation of fragile growths on the inner surface of the auricle for the last 1 month. The animal was an 8-month-old, unspayed female Scottish fold shorthair cat weighing 2.9 kg, with a white coat, never been in heat. According to the anamnesis, the cat had no previous allergic reaction to any substance and was fed with generic, pellet cat food by the owner. At least three times a week paste treats and wet food products were giving the cat. The lesions were first noticed by the owner as black dots like earwax and progressed rapidly and soon covered the entire inner surface of the auricle (Figure 1-A). During this process, owner observed loss of appetite and weakness. The cat had been treated for 21 days with a topical ear cleanser and an ear pomade containing neomycin, nystatin, triamcinolone acetonide, and permethrin, but no improvement in lesions was observed.

Clinical examination revealed that the lymph nodes were of normal size. Body temperature, heart rate, respiratory rate, and CRT were in normal range. It was observed that there were fragile, papillomatous and exudative growths on the concave surface of the pinna, and these growths continued until the entrance of the vertical ear canal. The external ear canal was partially filled with caseous purulent exudate, and when palpation was applied, the caseous contents came out. Otoscopic evaluation was not possible during the initial examination due to the lesions occluded the ear canal. Wood's lamp examination was negative for fungal infection.

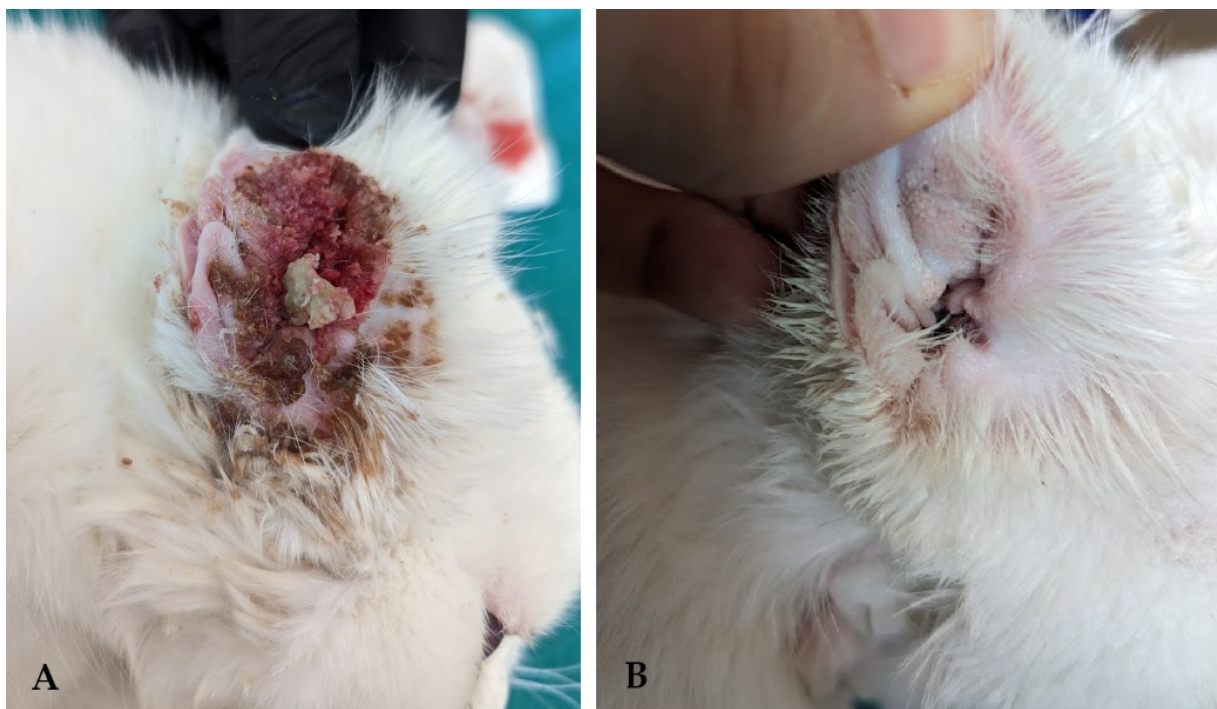
Sampling was performed under anesthesia (0.1 mg/kg butorphanol, 0.04 mg/kg medetomidine, 1.5 mg/kg ketamine IM) for histopathological examination. In view of the clinical presentation, the diagnosis of proliferative necrotic otitis externa was established, and a methylprednisolone SC injection of 3 mg/kg was administered into the auricle during the same anesthetic session. Owner was advised to clean auricals with Crystalin<sup>®</sup> containing hypochlorous acid and then to apply thin layer of mixture of Tacrolin<sup>®</sup> pomade and Furacin<sup>®</sup> pomade on the concave surface of the auricle 2 times. Systemically,

Synulox<sup>®</sup> was prescribed for 7 days. Elizabeth collar was recommended to be used. It was recommended to switch from generic cat food to hypoallergenic commercial food and to reduce the frequency of wet food and treats for the diet.

For the complaint of epiphora, the obstruction of the nasolacrimal ducts was checked, and it was found normal. Conjunctivae were inflamed and there was serous discharge in the eyes. Tobradex<sup>®</sup> eye drops were prescribed every 4 hours for the first three days and every 6 hours for the following days.

#### Processing of samples

Specimens were processed routinely for fixation in 10% neutral buffered formalin, sectioning at 5  $\mu$ m and staining with haematoxylin and eosin. In addition, Gram and PAS staining was carried out on the skin biopsies from extra-auricular lesions.

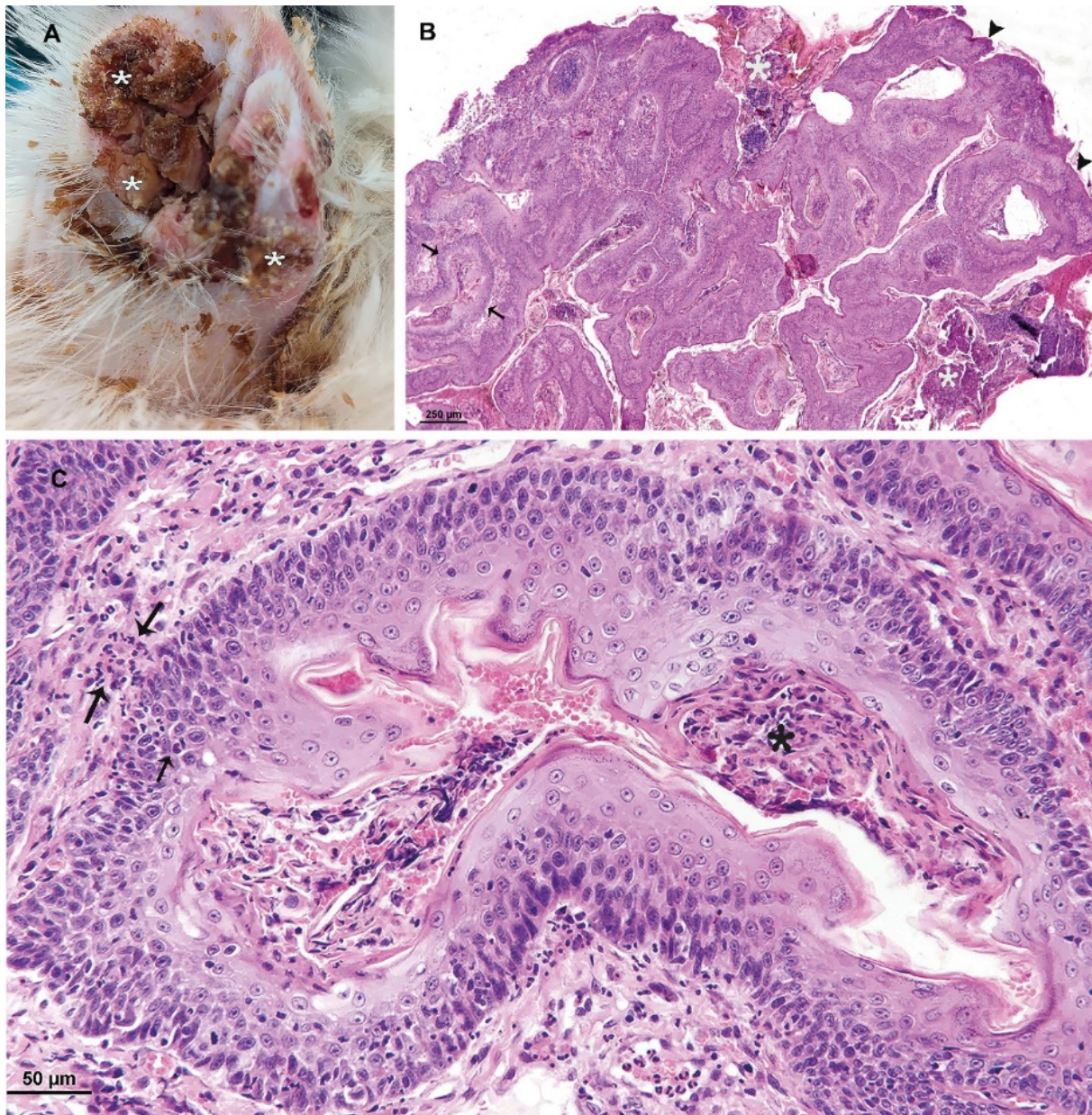


**Figure 1.** **A)** Proliferative formations in the inner surface of the pinna at the first evaluation. **B)** View of the inner pinna at two months after the initial treatment.

#### RESULTS AND DISCUSSION

Histopathologically, there were the small erosions and ulcers in the epidermis, and markedly acanthotic appearance in the epidermis and external root sheaths. The accumulations of cell debris were also observed on the acanthotic epidermis. Hyperplastic follicular external root sheath contained brightly eosinophilic and necrotic keratinocytes. In addition, the exocytosis of neutrophilic and lymphocytic cells from the dermis into the hyperplastic follicular external root sheath and numerous mitotic figures in keratinocytes of hyperplastic follicular sheaths noted. The inflammatory cell infiltrates consisted of plasma cells, lymphocytes, mast cells and neutrophils were observed in the dermis (Figure 2. A B C).





**Figure 2.** Feline proliferative and necrotizing otitis externa in a kitten with extensive extra-auricular formations.

(A) Shows the light brown to dark erythematous vegetative plaque with adherent keratinous debris lining the inner part of the pinna and the canal (\*). There are also small erosions or ulcers on the inner part of the auricle.

(B) Showing markedly acanthotic appearance the epidermis (arrowheads) and external root sheaths (arrows). Accumulation of cell debris (\*) is observed on the acanthotic epidermis. (C) Higher magnification of the acanthotic root sheath between the arrows in picture B. Showing brightly eosinophilic and necrotic keratinocytes (parakeratotic hyperkeratosis) (\*) the exocytosis of neutrophilic and lymphocytic cells from the dermis into the hyperplastic follicular outer root sheath (arrows).

At the first control, after the 1 week of initial treatment, it was determined that the discharge from the ear canal had stopped and the proliferative lesions on the concave surface of the auricle had regressed. It was also learned that the pomades caused itching in the ears. The appetite was increased.

Hemogram and biochemistry values of the blood samples were found to be normal.

Two weeks after the first examination, the use of Furacin<sup>®</sup> pomade was discontinued because the exudation and secondary infection in the lesions disappeared. During the follow-up visits of one-week intervals, the lesions gradually regressed, and the general condition improved. About one month after the first visit, 99% of the lesions had disappeared and otoscopic examination showed no growths in the ear canal. Tacrolin<sup>®</sup> pomade and Crystalin<sup>®</sup> spray were recommended for 2 more weeks. After 2 months, it was determined that minimal sequelae (blackheads) remained on the auricle (Figure 2).

Plasma cell pododermatitis, papilloma virus, and fungal infections are important in the differential diagnosis of the disease. Papillomavirus (PV) is a causative agent of hyperplastic growths in cats (Munday and Thomson, 2021). Progression of the PV-associated lesions suggest a cause, such as stress, and it should be kept in mind that glucocorticoids may trigger virus expression and enhance the development of use-associated lesions. Since exposure to PV or other viral agents causes increased sensitization, topical and oral glucocorticoid use is generally contraindicated (Nagata and Rosenkrantz, 2013).

In our case, both topical application of tacrolimus pomade and local prednisolone injections were performed. In contrast, a very rapid regression of the lesions was observed.

Plasma cell pododermatitis is a disease of uncertain etiology that causes lesions in the ears and pulvinus and usually responds to immunomodulatory treatment (Brosseau, 2022).

In our case, although there were lesions in the ears, there were no lesions in the pulvinus, and it responded to treatment based on the principle of immunosuppression.

Wood's lamp is a source of long wave ultraviolet light and has diagnostic utility in detecting fluorescence in skin and hair, a characteristic of some dermatophytes in infected skin and hair that is invisible to the naked eye (Al Aboud and Gossman, 2022). It is differentiated from fungal infection by the fact that the lesions were confined to the ear and the Wood's lamp test was negative.

It has been noted that the main diagnostic microscopic lesions of proliferative otitis externa are characterized by papillomatous hyperplasia and follicular epidermal hyperplasia with hyperkeratosis and parakeratotic hyperkeratosis of the epidermis, necrotic neutrophilic crusting covering the epidermal surface and obstructing the hair follicle ducts. It was also reported that single cell necrosis/apoptosis in different layers of the epidermis, marked lymphocytic exocytosis and satellitosis of dead keratinocytes. In addition, it has been noted that in the dermis, depending on the duration of inflammation, inflammatory cell infiltrates typically consist of plasma cells, lymphocytes, mast cells and neutrophils (Mauldin *et al.*, 2007; Brian & Bradley, 2015; Momota *et al.*, 2016; Panzuti *et al.*, 2021). The histopathological findings of presented herein was very similar for those described by Mauldin *et al.*, 2007; Momota *et al.*, 2017; Panzuti *et al.*, 2021. However, inflammatory cell infiltrations in the dermis were differently observed to consist of lymphocytes and neutrophils. Based on these characteristic histopathological findings, presented herein a diagnosis of proliferative and necrotizing otitis was made.

In conclusion, despite the unknown etiology of PNOE, the response of the disease to immunosuppressive therapy is quite remarkable. This situation contributes to both the diagnosis and treatment of the disease.



### **Ethical Approval**

This manuscript is a case report. It is not required any institutional ethics approval for case reports. We have informed consent document from the owner.

### **Conflict of Interest**

Authors have no conflict of interest to declare. All authors contributed to the study conception and design. Material preparation, data collection and analysis were performed by Caner KAYIKCI, Ömer Faruk KELEŞ, Yağmur KUŞCU, Selime Nur EKICI and Hacı Ahmet ÇİÇEK. The first draft of the manuscript was written by Caner KAYIKCI and all authors commented on previous versions of the manuscript. All authors read and approved the final manuscript.

### **REFERENCES**

- Al Aboud, D.M., & Gossman, W. (2022), Wood's Light, StatPearls Publishing, Treasure Island (FL).
- Borio, S., Massari, F., Abramo, F., & Colombo, S. (2012), Proliferative and necrotising otitis externa in a cat without pinnal involvement: video-otoscopic features. *Journal of Feline Medicine and Surgery* 15(4), 353–356.
- Brian, P.W. & Bradley, L.N. (2015), Special Senses. In: Jubb KVF, Kennedy PC and Palmer N (eds.), Pathology of domestic animals, vol. 1, 6th edition, Academic Press, London, 502–503.
- Brosseau, G. (2022), Feline plasma cell pododermatitis. *The Canadian Veterinary Journal* 63(5), 545.
- Gross, T.L., Ihrke, P.J., Walder, E.J., & Affolter, V.K. (2008), Necrotizing diseases of the epidermis, Skin diseases of the dog and cat: clinical and histopathologic diagnosis, John Wiley & Sons, 79–91.
- Mauldin, E.A., Ness, T.A., & Goldschmidt, M.H. (2007), Proliferative and necrotizing otitis externa in four cats. *Veterinary Dermatology*, 18(5), 370–377.
- Momota, Y., Yasuda, J., Ikezawa, M., *et al.* (2016), Proliferative and necrotizing otitis externa in a kitten: successful treatment with intralesional and topical corticosteroid therapy. *Journal of Veterinary Medical Science*, 78(12), 1883-1885.
- Munday, J.S., & Thomson, N.A. (2021), Papillomaviruses in domestic cats. *Viruses*, 13(8), 1664.
- Nagata, M., & Rosenkrantz, W. (2013), Cutaneous viral dermatoses in dogs and cats. *Compendium (Yardley, PA)* 35 (7), E1–E1.
- Panzuti, P., Jongh, O., Dony, M., Vial, S., Mosca, M., & Pin, D. (2021), Extra-auricular lesions of proliferative and necrotizing otitis externa in three kittens. *Veterinary Dermatology* 32(4), 385-e110.
- Sanders, S., Busam, K.J., Halpern, A.C., & Nehal, K.S. (2002), Intralesional Corticosteroid Treatment of Multiple Eruptive Keratoacanthomas: Case Report and Review of a Controversial Therapy, *Dermatologic Surgery* 28(10).
- Vidémont, E., & Pin, D. (2010), Proliferative and necrotising otitis in a kitten: first demonstration of T-cell-mediated apoptosis. *Journal of Small Animal Practice* 51(11), 599–603.